



Contents lists available at ScienceDirect

International Journal of Surgery Case Reports

journal homepage: www.elsevier.com/locate/ijscr



Case report

Intramuscular cavernous haemangioma of the triceps

D.K. Patten^{a,b}, Z. Wani^c, S. Kamineni^{d,*}

^a Department of Biosurgery and Surgical Oncology, St Mary's Hospital, Imperial College Healthcare Trust, London, UK

^b Imperial College London, South Kensington, London, UK

^c Department of Haematology, Churchill Hospital, Oxford, UK

^d Department of Elbow-Shoulder-Upper Extremity Surgery, Kentucky Clinic, University of Kentucky, Kentucky, USA

ARTICLE INFO

Article history:

Received 16 December 2010

Received in revised form 9 February 2011

Accepted 21 February 2011

Available online xxx

Keywords:

Cavernous haemangioma

Haemangioma

Triceps

Intramuscular haemangioma

ABSTRACT

Haemangiomas are one of the most common soft tissue tumours comprising 7% of all benign tumours. Vascular malformations are often confused with haemangiomas. The etiology is unknown. They are common in infancy and childhood and females are more commonly affected. These tumours may be superficial or deep, and deeply seated lesions, are difficult to diagnose clinically and hence require radiographic assessment. Deep-seated haemangiomas are usually intramuscular, although intra-articular synovial haemangiomas also occur. The commonest anatomic site is the lower limb.

Despite their vascular origin, haemangiomas do not metastasize or undergo malignant transformation. Many treatment modalities for the symptomatic haemangioma are available but surgical excision is the preferred treatment. We present an unusual case of a dumb-bell intramuscular haemangioma involving the triceps and extending into the cubital tunnel of the elbow, distinguish between haemangiomas and vascular malformations and emphasize the importance of surgical technique in ensuring ulnar nerve safety.

© 2011 Surgical Associates Ltd. Elsevier Ltd. All rights reserved.

1. Introduction

Haemangiomas are the most common benign soft tissue tumour of infancy and childhood comprising 7% of all soft tissue tumours.¹ The etiology is unclear but possibly congenital in origin.^{1–5} Haemangiomas commonly occur in the skin or subcutaneous tissues followed by the deep tissues, occasionally are intramuscular and rarely within bone. There is a general agreement that females are more commonly affected than males.^{5,6}

The most common site of ulnar nerve compression is the elbow although cavernous haemangioma in the triceps causing this complication has not yet been reported. We report such a case where the ulnar nerve has been encapsulated by the tumour and describe the surgical technique used to remove the tumour, clarify differences between haemangioma and vascular malformations and emphasize the importance of surgical technique to ensure safety of the ulnar nerve.

2. Case report

A 15 year-old right handed female presented to the elbow clinic with a 4 year history of gradually increasing left elbow pain

and swelling, without a history of trauma. The swelling gradually increased in size and the patient was occasionally woken at night with intense pain. There was no significant past medical history.

Physical examination revealed a diffuse ill-defined firm soft tissue swelling approximately 6 cm × 2.5 cm in the posteromedial aspect of the elbow. There was no skin tethering or any skin changes. The swelling was tender on palpation, with no palpable thrill or audible bruit, and no adjacent bony tenderness. The ulnar nerve was in the cubital tunnel, non-subluxable, and non-irritable, with a negative Tinel's sign. Neurovascular examination was normal, and no palpable axillary lymph nodes were present. Active elbow motion ranged from 5° of hyperextension to 135° of flexion, and 80° pronation and 80° supination. There was no varus, valgus or rotational instability.

Conventional radiography (Fig. 1) of the left elbow revealed soft tissue swelling without any phlebolith or periosteal reaction.

Magnetic resonance imaging (MRI) showed an hourglass lobulated soft tissue mass in the posteromedial aspect of the elbow. An intermediate signal corresponding to triceps tissue was present on T2 weighted sagittal and axial images (Fig. 2). On T2 weighted, fat suppressed, sagittal and axial images a lesion with a high intensity signal was visualized (Fig. 3A and B).

The patient underwent open surgery at which a highly vascular soft tissue mass within the triceps was observed (Fig. 4). The ulnar nerve was found to be inherently encapsulated by the waist of the tumour, within the cubital tunnel, and was dissected free of the tumour. In order to ensure safety of the ulnar nerve, the nerve was

* Corresponding author.

E-mail address: srinathkamineni@gmail.com (S. Kamineni).

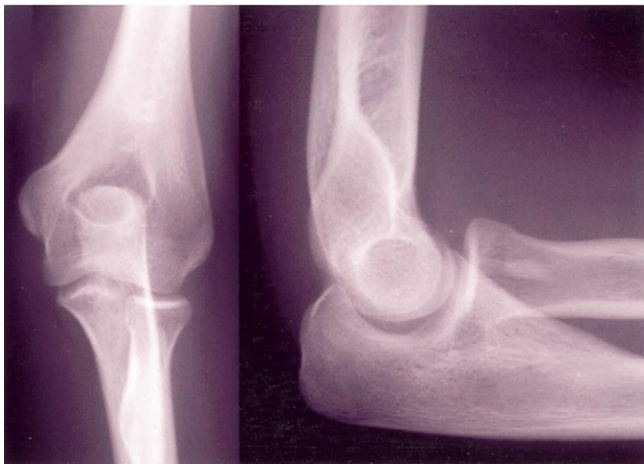


Fig. 1. Anteroposterior and lateral X-ray of the elbow showing soft tissue swelling without any phlebolith or periosteal reaction.

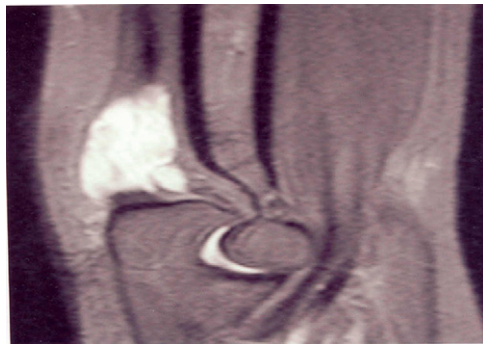


Fig. 2. MRI showing a mass in the posteromedial aspect of the elbow with an intermediate signal similar to triceps seen on T2 weighted images.

identified proximal to the medial epicondyle by 3 cm, and then followed into the tumour region by developing the peri-neural plane. It was important to keep ulnar nerve dissection to the perineural layer as it was not infiltrated by the tumour. Regular use of vessel tying off and bipolar diathermy was performed to control bleeding. The nerve was left in situ within the cubital tunnel. The vascular element appeared to be predominantly venous, and the tumour

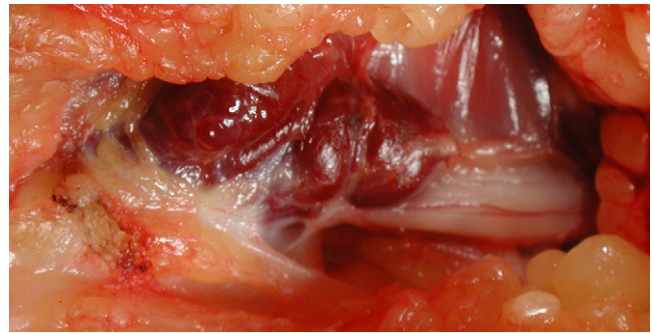


Fig. 4. Macroscopic appearance of the highly vascular soft tissue mass seen within the triceps. The ulnar nerve is seen encapsulated by the waist of the tumour.

was excised with a margin of normal triceps muscle (Fig. 5). Post-operative recovery was unremarkable and the ulnar nerve function remained normal. The active range of motion remained at the pre-operative level, and no post-operative instability was present.

3. Histopathology evaluation

Histopathological examination showed large angiomatous spaces dissecting between adipose tissue and skeletal muscle bundles, some of which were in direct continuity with the adventitia of the vascular spaces. Skeletal muscle was the major element with adipose tissue the next largest component. Recanalisation of the vascular spaces was also apparent with haemosiderin deposition and endothelial cells forming small capillary sprouts (Fig. 6). All the above features were suggestive of intramuscular cavernous haemangioma.

4. Discussion

The term “haemangioma” is commonly misused to describe any type of vascular abnormality, including vascular malformation, in both medical and surgical fields.⁷ Hassanein et al. revealed in a study that the term was incorrectly used in 71.3 percent of publications on the Pubmed database.⁸ Venous malformation can occur in every muscle group with pain and swelling being the usual complaints. Vascular malformations are usually present at birth, grows proportionally with the child and

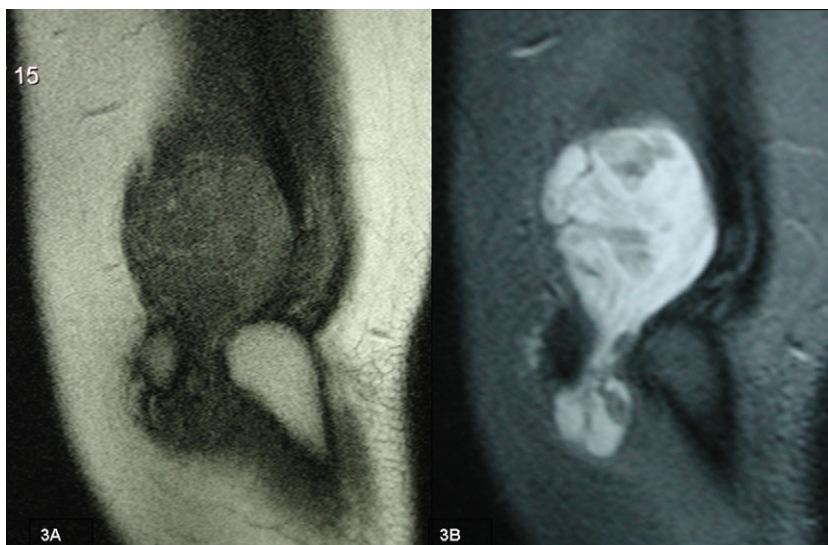


Fig. 3. MRI showing an hourglass lobulated soft tissue mass in the posteromedial aspect of the elbow seen on T1 (A) and T2 (B) weighted and fat suppressed sagittal images.

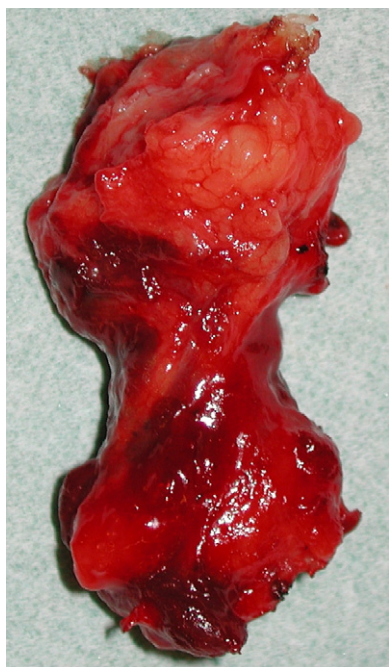


Fig. 5. Post excision macroscopic appearance of the hourglass mass with a margin of normal triceps muscle.

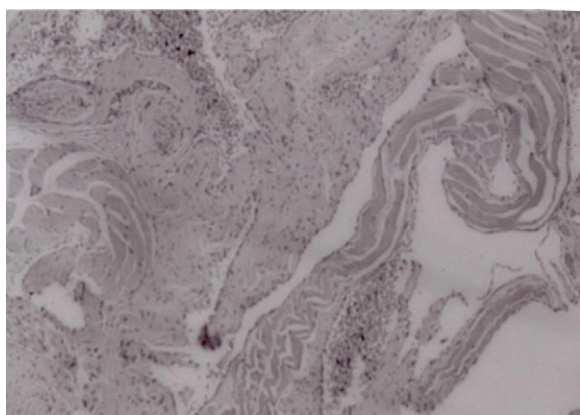


Fig. 6. Microscopic appearance of mass showing large angiomatic spaces dissecting between adipose tissue and skeletal muscle bundles, some of which are in direct continuity with the adventitia of the vascular spaces are seen. Recanalisation of the vascular spaces is also apparent with haemosiderin deposition and endothelial cells forming small capillary sprouts [$\times 10$, haematoxylin and eosin].

never involutes. They can be classified as arterial, arteriovenous, venous, capillary or lymphatic. Haemangiomas are distinguished by endothelial hyperplasia, multilaminated basement membrane formation beneath the endothelium and clinical history of rapid growth during infancy.⁹ Additionally, intramuscular venous malformation can be distinguished from cavernous haemangioma as the former has no regression phase and certain MRI characteristics (see below).

Histologically haemangiomas are classified based on the predominant type of vascular channel as follows¹⁰:

1. Capillary haemangioma, which are composed of small vessels lined by flattened endothelium. It is the commonest type and subdivided into juvenile, verrucous and senile type.
2. Cavernous haemangioma, which are composed of dilated, blood filled spaces, lined by flattened endothelium. There is abundant

adipose tissue and they do not involute as the capillary haemangioma.

3. Arteriovenous haemangioma, which is characterized by the presence of fetal capillary bed with abnormal communication of the arteries and veins.
4. Venous haemangioma, which is composed of thick walled vessels containing muscle.

Intramuscular haemangiomas account for 0.8% of all haemangiomas.^{1,5} The latter occur most commonly in young adults with 80–90% presenting in individuals younger than 30 years.^{1,5} Clinically they manifest with a mass without any diagnostic features. Pain is a cardinal symptom in 60% of the cases,¹ with the lower extremity being the commonest site of involvement. The quadriceps is the most frequently affected muscle.^{11,12} Intramuscular haemangiomas progressively enlarge but never metastasize.² There is a 9% recurrence rate after surgical excision.¹

Plain radiographs of soft tissue haemangioma may appear only as a non-specific soft tissue mass and in 25–30% of cases it shows phlebolith.^{1,10} Periosteal reaction adjacent to the haemangioma may mimic osteomyelitis or bone tumour.

MRI is important for further characterization of the substance and extent of the soft tissue haemangioma. On T1-weighted images, a haemangioma appears as low-to-intermediate signal intensity mass with peripheral high signal intensity due to fat overgrowth. On T2-weighted images, it shows areas of high signal intensity due to vascular tissue and intermediate signal intensity due to fat. MRI shows venous malformations to be isointense to surrounding muscle on T1-weighted and hyperintense on T2-weighted images. Characteristic tubular or serpentine components are orientated along the muscular long axis. Thrombi are hyperintense on T1-weighted and hypointense on T2-weighted sequences.⁷

MRI may also help to differentiate between types of haemangiomas. Lesions with large cystic spaces are cavernous whereas arteriovenous haemangiomas show more prominent fast flow serpentine vessels. Venous haemangiomas, on the other hand, show slow-flow serpentine vessels.

Angiography should be considered if MRI has not provided sufficient information about the relationship between the tumour and a neurovascular bundle.¹³

In patients in whom excision is impractical, embolization or radiotherapy should be considered. In cases of recurrence adjuvant therapy (interferon- α) may be considered.

Current literature reports intramuscular arteriovenous haemangioma,¹⁴ intramuscular venous malformation¹⁵ and haemangioma of antibrachial flexor muscles¹⁶ in the upper arm causing ulnar nerve compression. In this case we present, a unique feature was that the ulnar nerve was encapsulated by the cavernous haemangioma, which had a dumbbell configuration. This was discovered during the operation and so highlights the importance of identifying ulnar nerve involvement in medial elbow tumours pre-operatively. Ulnar nerve safety by identification and developing of the peri-neural plane was paramount in the surgical technique in addition to regular vessel tying-off and bipolar diathermy to control bleeding.

Funding

None.

Conflicts of interest statement

None.

Ethical approval

Written informed consent was obtained from the patient for publication of this case report and accompanying images.

Acknowledgement

The author would like to thank Dr Williamson for his pathological report and the photomicrograph.

References

1. Allan PW, Enzinger FM. Haemangioma of skeletal muscle: an analysis of 89 cases. *Cancer* 1972;**29**:8-22.
2. Ferguson ILC. Haemangiomata of skeletal muscle. *Br J Surg* 1972;**59-8**:634-7.
3. Jones KG. Cavernous haemangioma of striated muscle—a review of literature and a report of four cases. *J Bone Joint Surg* 1953;**35A**:717-28.
4. Mencke HJ, Zilkens J, Bigalke KH, Ammon J. The problem of intramuscular haemangioma. *Arch Orthop Trauma Surg* 1982;**100**:243-7.
5. Watson WL, McCarthy WD. Blood and lymph vessel tumors. A report of 1056 cases. *Surg Gynecol Obstet* 1940;**71**:569-88.
6. Beham AJ, Fletcher CDM. Intramuscular angioma: a clinicopathologic analysis of 74 cases. *Histopathology* 1991;**18**:53-9.
7. Mulliken JB, Glowacki J. Haemangiomas and vascular malformations in infants and children: a classification based on endothelial characteristics. *Plast Reconstr Surg* 1982;**69**:412-22.
8. Hassanein AH, Mulliken JB, Fishman SJ, Greene AK. Evaluation of terminology for vascular anomalies in current literature. *Plast Reconstr Surg* 2011;**127**(1):347-51.
9. Fernandez-Pineda I. Intramuscular cavernous haemangioma. *Am J Surg* 2009;**198**(2):300-1.
10. Hein KD, Mulliken JB, Kozakewich HP, Upton J, Burrows PE. Venous malformations of skeletal muscle. *Plast Reconstr Surg* 2002;**110**:1625-35.
11. Buetow PC, Kransdorf MJ, Moser Jr RP, Jelinek JS, Berrey BH. Radiographic appearance of intramuscular hemangioma with emphasis on MR imaging. *Am J Roentgenol* 1990;**154**:563-7.
12. Christenson JT, Gunterberg B. Intramuscular haemangioma of the extremities: is computerized tomography useful? *Br J Surg* 1985;**72**:748-50.
13. McNeill TW, Chan GE, Capek V, Ray RD. The value of angiography in the surgical management of deep hemangiomas. *Clin Orthop* 1974;**101**:176-81.
14. Pulidori M, Capuano C, Mouchaty H, Cioffi F, Di Lorenzo N. Intramuscular thrombosed arteriovenous hemangioma of the upper right arm mimicking a neuroma of the ulnar nerve: case report. *Neurosurgery* 2004;**54**(3):770-1.
15. Muchemwa FC, Ishihara T, Matsushita S. Intramuscular venous malformation in the upper arm with gross calcifications and compression of the ulnar nerve. *Scand J Plast Reconstr Surg Hand Surg* 2007;**41**(2):93-5.
16. Ouarab M, Rahmi M, Harfaoui A, Hassoun J, Trafef M. Ulnar nerve haemangioma associated with haemangioma of the epitrochlear muscles. A case report. *Ann Chir Main Memb Super* 1997;**16**(4):339-41. French.

Open Access

This article is published Open Access at sciedirect.com. It is distributed under the [IJSCR Supplemental terms and conditions](#), which permits unrestricted non commercial use, distribution, and reproduction in any medium, provided the original authors and source are credited.