

Arteriosclerosis, Thrombosis, and Vascular Biology

JOURNAL OF THE AMERICAN HEART ASSOCIATION



Vitamin E Inhibits Abdominal Aortic Aneurysm Formation in Angiotensin II-Infused Apolipoprotein E-Deficient Mice

Dan Gavrilu, Wei Gen Li, Michael L. McCormick, Manesh Thomas, Alan Daugherty, Lisa A. Cassis, Francis J. Miller, Jr, Larry W. Oberley, Kevin C. Dellsperger and Neal L. Weintraub

Arterioscler. Thromb. Vasc. Biol. 2005;25;1671-1677; originally published online Jun 2, 2005;

DOI: 10.1161/01.ATV.0000172631.50972.0f

Arteriosclerosis, Thrombosis, and Vascular Biology is published by the American Heart Association.
7272 Greenville Avenue, Dallas, TX 75214

Copyright © 2005 American Heart Association. All rights reserved. Print ISSN: 1079-5642. Online ISSN: 1524-4636

The online version of this article, along with updated information and services, is located on the World Wide Web at:

<http://atvb.ahajournals.org/cgi/content/full/25/8/1671>

Subscriptions: Information about subscribing to Arteriosclerosis, Thrombosis, and Vascular Biology is online at
<http://atvb.ahajournals.org/subscriptions/>

Permissions: Permissions & Rights Desk, Lippincott Williams & Wilkins, 351 West Camden Street, Baltimore, MD 21202-2436. Phone 410-5280-4050. Fax: 410-528-8550. Email:
journalpermissions@lww.com

Reprints: Information about reprints can be found online at
<http://www.lww.com/static/html/reprints.html>

Vitamin E Inhibits Abdominal Aortic Aneurysm Formation in Angiotensin II–Infused Apolipoprotein E–Deficient Mice

Dan Gavrilu, Wei Gen Li, Michael L. McCormick, Manesh Thomas, Alan Daugherty, Lisa A. Cassis, Francis J. Miller Jr, Larry W. Oberley, Kevin C. Dellsperger, Neal L. Weintraub

Background—Abdominal aortic aneurysms (AAAs) in humans are associated with locally increased oxidative stress and activity of NADPH oxidase. We investigated the hypothesis that vitamin E, an antioxidant with documented efficacy in mice, can attenuate AAA formation during angiotensin II (Ang II) infusion in apolipoprotein E–deficient mice.

Methods and Results—Six-month-old male apolipoprotein E–deficient mice were infused with Ang II at 1000 ng/kg per minute for 4 weeks via osmotic minipumps while consuming either a regular diet or a diet enriched with vitamin E (2 IU/g of diet). After 4 weeks, abdominal aortic weight and maximal diameter were determined, and aortic tissues were sectioned and examined using biochemical and histological techniques. Vitamin E attenuated formation of AAA, decreasing maximal aortic diameter by 24% and abdominal aortic weight by 34% ($P<0.05$, respectively). Importantly, animals treated with vitamin E showed a 44% reduction in the combined end point of fatal+nonfatal aortic rupture ($P<0.05$). Vitamin E also decreased aortic 8-isoprostane content (a marker of oxidative stress) and reduced both aortic macrophage infiltration and osteopontin expression ($P<0.05$, respectively). Vitamin E treatment had no significant effect on the extent of aortic root atherosclerosis, activation of matrix metalloproteinases 2 or 9, serum lipid profile, or systolic blood pressure.

Conclusions—Vitamin E ameliorates AAAs and reduces the combined end point of fatal+nonfatal aortic rupture in this animal model. These findings are consistent with the concept that oxidative stress plays a pivotal role in Ang II–driven AAA formation in hyperlipidemic mice. (*Arterioscler Thromb Vasc Biol.* 2005;25:1671-1677.)

Key Words: aneurysm ■ vitamin E ■ oxidative stress ■ vascular inflammation ■ NADPH oxidase ■ osteopontin

Abdominal aortic aneurysms (AAAs) occur in $\approx 3\%$ of humans >65 years of age and are characterized by localized structural deterioration of the aortic wall, leading to progressive aortic dilation. The most dreaded complication of AAA is rupture, the likelihood of which is directly related to aneurysm diameter.¹ Although open surgical repair can improve outcomes in patients with large AAAs, the procedure is associated with significant operative risks and complications, particularly in the presence of comorbid conditions common in these patients. Percutaneous repair techniques (ie, stent grafting) have been developed, but not all patients are candidates, and these procedures are also associated with significant complications.² The development of effective medical therapy for AAA has been hampered by lack of understanding of the mechanisms responsible for aneurysm growth and rupture.

Studies published over the past decade support the view that inflammation plays a key role in the pathogenesis of AAAs.^{3–7} One of the known causes and consequences of inflammation is an increase in local levels of oxidative stress.

Indeed, Miller et al have shown that human aneurysmal aorta displays clear evidence of increased oxidative damage and pro-oxidant enzyme expression/activity compared with adjacent nonaneurysmal tissue.⁸ Whether oxidative stress is merely associated with AAAs, or whether it contributes to the pathogenesis of the disease, remains to be determined.

In the present study, we examined the effects of vitamin E, a dietary antioxidant with proven efficacy in mice, in the murine angiotensin II (Ang II) infusion AAA model. In this model, infusion of Ang II for 4 weeks in apolipoprotein E (apoE)-deficient male mice results in formation of AAAs in 90% to 100% of these animals.^{9,10} We demonstrate that vitamin E has a marked impact on both aneurysm formation and its consequences (ie, rupture). These findings are consistent with the view that oxidative stress contributes to the pathophysiology of AAAs.

Materials and Methods

Six-month-old male apoE-deficient mice were randomly assigned to one of 3 groups: infusion (via osmotic minipumps) of normal saline

Original received December 1, 2004; final version accepted May 2, 2005.

From the Department of Internal Medicine (D.G., W.G.L., M.L.M., M.T., F.J.M., N.L.W.), University of Iowa, Iowa City; the Free Radical and Radiation Biology Program (M.L.M., F.J.M., L.W.O., N.L.W.), Department of Radiation Oncology, University of Iowa, Iowa City; Veterans Administration Medical Center (N.L.W.), Iowa City; the Department of Internal Medicine (A.D.), University of Kentucky, Lexington; the Graduate Center for Nutritional Sciences (L.A.C.), University of Kentucky, Lexington; and the Department of Internal Medicine (K.C.D.), University of Missouri, Columbia.

Consulting Editor for this article was Peter Libby, MD, Brigham and Women's Hospital, Boston, Mass.

Correspondence to Dr Neal L. Weintraub, Dept of Internal Medicine, University of Iowa College of Medicine, 200 Hawkins Dr, E-329GH, Iowa City, IA 52242. E-mail neal-weintraub@uiowa.edu

© 2005 American Heart Association, Inc.

Arterioscler Thromb Vasc Biol. is available at <http://www.atvbaha.org>

DOI: 10.1161/01.ATV.0000172631.50972.0f

Effects of Vitamin E and Ang II on SBP and Lipids in ApoE-Deficient Mice

	Control	Ang II	Ang II+vitE
Systolic blood pressure, mm Hg			
Pre-Ang II	107±8	107±5	105±4
Week 1	113±13	148±5*	152±6*
Week 2	105±6	156±5*	147±10*
Week 3	100±4	154±6*	147±9*
Week 4	95±4	148±7*	140±16*
Lipid fractions, mg/dL			
Total cholesterol	661±45	849±100	793±121
Triglycerides	88±6	202±62	116±20

SBP was measured using a computerized tail-cuff system 1 week before (pre-Ang II) and throughout the duration of Ang II infusion (n=10 for each). Lipid analysis was performed at the end of the study (control, n=3; Ang II and Ang II+vitamin E, n=6). All results are expressed as mean±SEM. **P*<0.05 compared with control. vitE indicates vitamin E.

(placebo control), Ang II (1000 ng/kg per minute), or Ang II plus dietary vitamin E (2 IU/g of diet). The experimental protocol was approved by the Institutional Animal Care and Use Committee at the University of Iowa and the Iowa City Veterans Administration Medical Center. For detailed methodologies^{11–14} of the various determinations, including statistical analysis, please see the online data supplement available at <http://atvb.ahajournals.org>.

Results**Vitamin E Did Not Affect Systolic Blood Pressure or Lipid Profile in This Experimental Model**

As hypertension is a documented risk factor for AAA enlargement and is induced by Ang II, we monitored this parameter in both control and treated apoE-deficient mice. Ang II infusion significantly increased systolic blood pressure (SBP), from a baseline of 106 mm Hg to 140 to 150 mm Hg (Table), within 48 hours after Ang II infusion, and persisted essentially unchanged throughout the study. No significant differences in SBP were observed at any time point between control and vitamin E-supplemented animals. Moreover, there was no correlation between SBP and either mortality or size of AAA (data not shown).

All animals developed severe hyperlipidemia, as expected in apoE-deficient mice (mean cholesterol, 789±51 mg/dL); however, neither infusion of Ang II nor dietary supplementation with vitamin E significantly affected the levels of total cholesterol or triglycerides determined at the conclusion of the study (Table). As evidence of the effectiveness of the vitamin E diet, we observed an ≈3-fold increase in plasma vitamin E levels in Ang II-infused mice supplemented with the vitamin E diet (Ang II only, 4.04±1.63 mg/L; Ang II+vitamin E, 12.26±5.59 mg/L; *P*<0.05, n=5, mean±SD).

Vitamin E Decreased AAA Diameter and Weight

After 4 weeks of Ang II or saline infusion, animals were euthanized, and aortae were isolated and examined for the presence of AAA. As previously reported, aneurysms of the suprarenal abdominal aorta were present in 90% of Ang II-treated mice (no vitamin E), whereas no saline-infused (control) animals developed AAAs.¹⁰ Twenty percent of

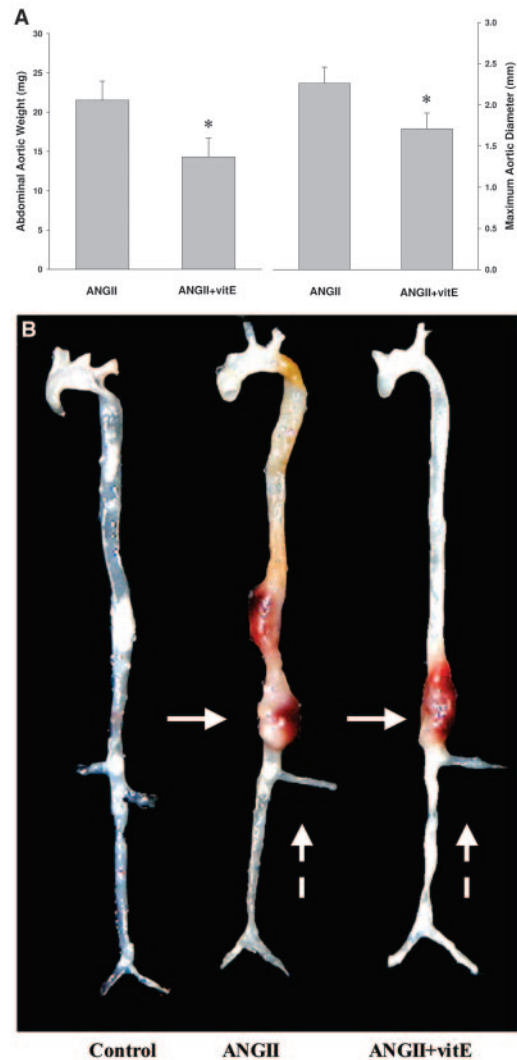


Figure 1. Vitamin E inhibited Ang II-induced AAA formation. A, Abdominal aortic weight and diameter in apoE-deficient, Ang II-infused mice (n=10 per group). **P*<0.05 vs Ang II. In control (saline-infused) mice, aortic weight was 4.4±0.5 mg and aortic diameter was 0.93±0.07 mm. B, Representative aortae from animals treated with saline (left), Ang II (ANGII) (center), and Ang II+vitamin E (ANGII+vitE) (right). Solid arrows point to the aortic aneurysms; dashed lines point to the renal arteries.

animals infused with Ang II only developed lower thoracic aorta aneurysms in addition to the AAAs. Periaortic inflammation was a prominent feature in animals that developed aneurysms, as evidenced by densely adherent periadventitial tissue that required microdissection to delineate the wall of the abdominal aorta.

Animals that received dietary vitamin E in addition to Ang II infusion showed a 24% reduction in maximal aortic diameter (*P*<0.05) and a 34% reduction in abdominal aortic weight (*P*<0.05) as compared with animals that received Ang II only (Figure 1A). The incidence of AAA formation in animals treated with vitamin E during infusion of Ang II was 60%. Lower thoracic aorta aneurysms were not observed in any Ang II-infused animals treated with vitamin E. Representative aortae from these mice are shown in Figure 1B. For comparison purposes, an aorta from a control mouse (saline-infused) is also shown.

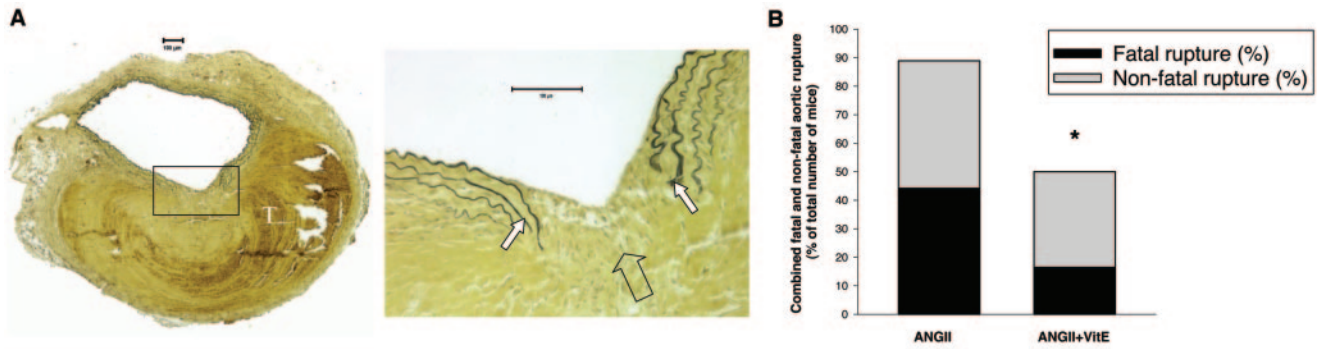


Figure 2. Vitamin E decreased the combined end point of fatal+nonfatal aneurysm rupture. A, Verhoeff Van Giessen-stained section (left, $\times 4$; right, $\times 20$) demonstrating elastin rupture. Medial elastin bands (white arrows) display an area of complete rupture (clear arrow), leading to thrombus formation (white letter T). B, Summary data showing percentages of animals with fatal and nonfatal aortic rupture following treatment with Ang II+dietary vitamin E. * $P < 0.05$ vs Ang II.

Vitamin E Decreased the Incidence of Fatal Plus Nonfatal AAA Rupture

We have defined aneurysm rupture as either (1) presence of thrombus detected visibly or by dissection microscopy (Figure 1B) or (2) microscopic confirmation of elastin band rupture with associated dissection and microthrombus formation in the vascular wall (Figure 2A). When these microscopic ruptures evolve into a complete rupture of the aortic wall, the result is death. Accordingly, all animals that died in the course of this study (before termination at 4 weeks) were determined to have aortic rupture at the time of necropsy. Each of these animals died unexpectedly, without premonitory signs of infection or other chronic illnesses. There were no deaths or aortic ruptures in saline-infused mice. Of the Ang II-infused animals consuming a regular diet, 44.5% died before the end of the study (fatal rupture, Figure 2B), 44.5% survived until the end of the study but had evidence of aortic rupture (nonfatal rupture, Figure 2B), and 11% survived with no detectable rupture. In contrast, of the animals infused with Ang II and cotreated with vitamin E, 17% died before the end of the study, 33% survived but had evidence of aortic rupture, and 50% survived with no detectable rupture. Thus, in Ang II-infused animals consuming a regular diet ($n=18$), the combined incidence of fatal+nonfatal rupture was 89%. Cotreatment with vitamin E ($n=12$) resulted in a 44% reduction in this combined end point ($P < 0.05$ versus Ang II alone) (Figure 2B).

Vitamin E Did Not Affect Development of Atherosclerosis at the Aortic Root

Because atherosclerosis is frequently observed in AAA patients, and because previous studies have reported that vitamin E can attenuate atherosclerosis formation in hyperlipidemic mice in the absence of Ang II infusion,^{15,16} we investigated whether vitamin E treatment modulated atherosclerosis of the aortic root in our experimental model. It is important to note that only those animals that survived for the duration of the study were included in this analysis. We found that Ang II induced a small, statistically insignificant, increase in the extent of aortic root atherosclerosis (Figure 1, available online at <http://atvb.ahajournals.org>), which was not affected by concurrent dietary vitamin E supplementation.

Vitamin E Decreased Formation of 8-Isoprostane in Abdominal Aorta

To examine whether vitamin E exerted an antioxidant effect in the abdominal aorta during AAA formation, we determined the concentration of 8-isoprostanes in aortic tissue homogenates. 8-Isoprostanes are stable products of membrane lipid peroxidation, and their tissue concentration correlates with the level of oxidative stress.¹⁷ Ang II treatment resulted in a >3 -fold increase in 8-isoprostane content in the abdominal aorta, which was markedly attenuated by dietary vitamin E supplementation ($P < 0.05$; Figure 3). This observed decrease in 8-isoprostane formation is consistent with vitamin E providing antioxidant protection in the tissue where AAA develops.

Vitamin E Decreased Macrophage Infiltration of the Aneurysmal Tissue

Inflammation plays an essential role in AAA, and macrophage infiltration is a critical part of the inflammatory process. Moreover, dietary vitamin E has been shown to reduce macrophage infiltration in the aortic root of hyperlipidemic mice.¹⁶ To determine whether vitamin E reduced

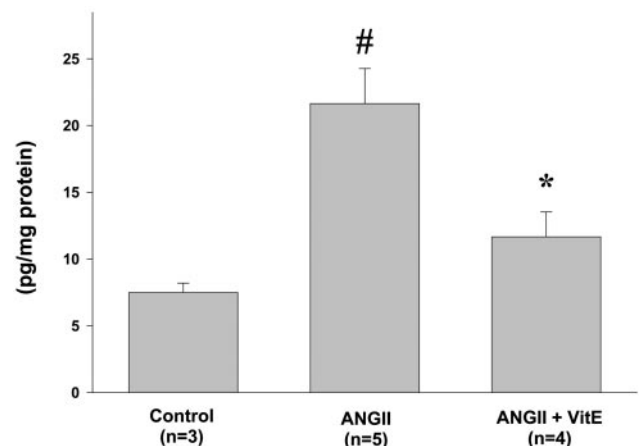


Figure 3. Vitamin E decreased oxidative stress in the abdominal aorta of apoE-deficient mice. 8-Isoprostane formation, determined by enzyme immunoassay, in abdominal aortae from apoE-deficient mice treated with vehicle (control, $n=3$), Ang II ($n=5$), and Ang II+vitamin E ($n=4$). Results are expressed per milligram of protein. # $P < 0.05$ compared with control, * $P < 0.05$ compared with Ang II.

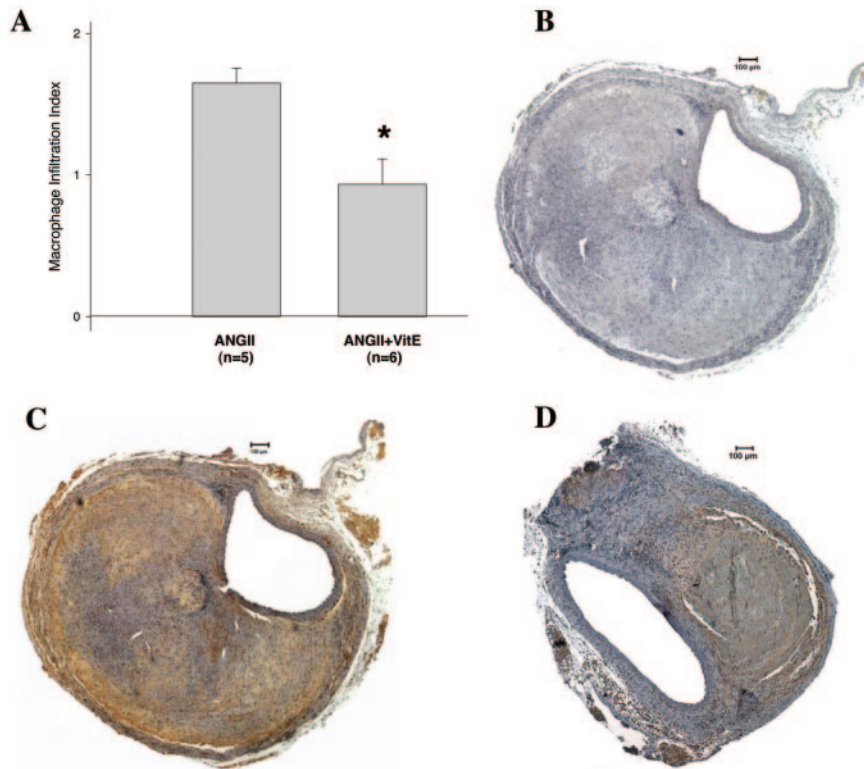


Figure 4. Vitamin E attenuated macrophage infiltration in abdominal aorta of Ang II-infused mice. A, Extent of macrophage infiltration in abdominal aortae from mice treated with Ang II or Ang II+vitamin E. * $P < 0.05$ compared with Ang II only. B through D, Representative photomicrographs showing immunohistochemical detection of macrophages (brown color represents positive staining for macrophages) in abdominal aorta from Ang II-treated mice. B, Negative control (no primary antibody). C, Ang II-infused without vitamin E treatment. D, Ang II-infused with vitamin E treatment.

tissue macrophage infiltration in AAA, serial tissue blocks prepared at the same distance from the point of maximal aortic diameter were examined. Two blinded investigators assigned a quantitative score to both the intensity of the macrophage staining (0 to 3) and to the percentage of area that stained positive for macrophages (0% to 100%). An index of macrophage infiltration was calculated by multiplying the 2 scores. We were thus able to demonstrate a 43% reduction in the macrophage infiltration index with vitamin E treatment ($P < 0.05$) (Figure 4A). In AAA tissues, the macrophage staining appeared to be much more prominent in the adventitia than in the media (Figure 4C and 4D). This is consistent with a recently published chronological study of AAA histology in the same animal model,¹⁸ where macrophage infiltration was first noted in the media of the abdominal aorta soon after initiation of Ang II infusion and became more prominent in the adventitia at later time points.

Effects of Vitamin E on Matrix Metalloproteinase 2 and Metalloproteinase 9 Activity, and Osteopontin Expression, in AAA

Because matrix metalloproteinases (MMPs), especially MMP-2 and MMP-9, play a critical role in AAA formation,¹⁹ and because the activity of MMPs may, in part, be redox regulated,²⁰ we examined MMP gelatinolytic activity in abdominal aortic tissue homogenates. As expected, Ang II infusion induced an increase in both MMP-2 and MMP-9 activity compared with control (saline infusion). Treatment with vitamin E, however, had no effect on either MMP-2 or MMP-9 activity in abdominal aortae of Ang II-infused mice (Figure 5A and 5B).

We also investigated the potential for vitamin E to modulate aortic expression of osteopontin (OPN), a signaling

protein first discovered in bone tissue and, more recently, shown to be involved in a variety of vascular diseases. Of interest to the present study, apoE-deficient mice that are also deficient in OPN are protected against Ang II-induced AAA formation,²¹ suggesting that OPN expression plays an important role in AAA development in this model. Moreover, there is evidence that OPN expression may be redox regulated.²²

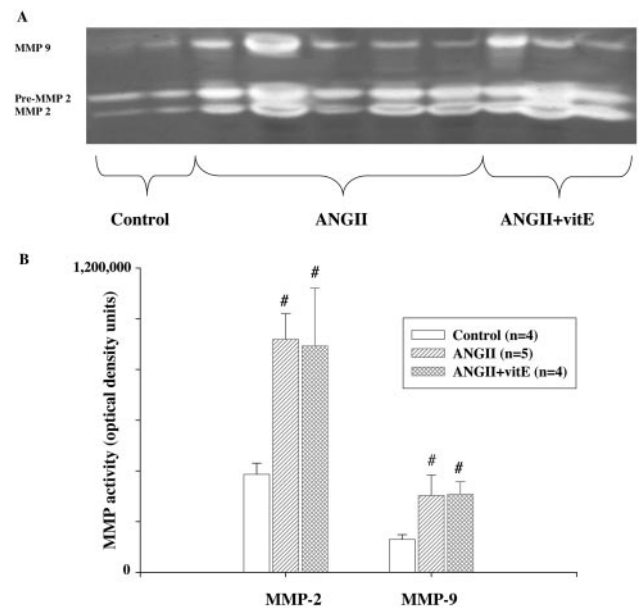


Figure 5. Vitamin E did not affect Ang II-induced increase in MMP-2 and MMP-9 activity. A, Representative zymogram of abdominal aortic tissue homogenates from control (saline infused), Ang II, and Ang II+vitamin E animals. B, Densitometric quantification of gelatinolytic activity. # $P < 0.05$ compared with control.

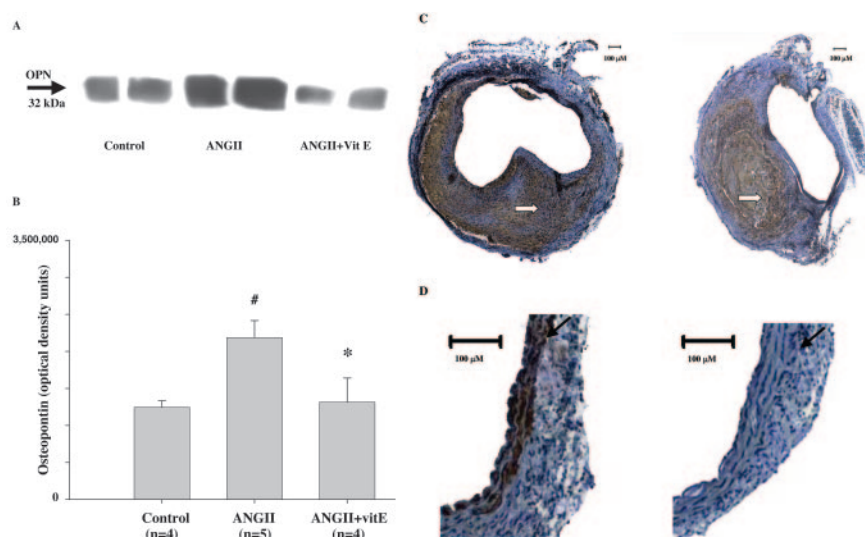


Figure 6. Vitamin E treatment ameliorated Ang II–induced increase in OPN expression. A, Representative immunoblot for OPN in abdominal aortic tissue homogenates. B, Densitometric quantification for OPN; [#] $P < 0.05$ compared with control, ^{*} $P < 0.05$ compared with Ang II. C and D, OPN immunostaining (brown color) in the absence (left) or presence (right) of vitamin E treatment (white arrow shows adventitia). D, Magnified portion, black arrows show approximate location of the internal elastic laminae.

We found that in apoE-deficient mice, Ang II infusion induced a marked increase in OPN expression, as determined by Western blotting, which was significantly reduced by treatment with vitamin E (Figure 6A and 6B). Immunostaining showed that vitamin E reduced OPN expression in both the adventitia and media of aorta from Ang II–infused mice (Figure 6C and 6D).

Discussion

Here, we demonstrate for the first time that vitamin E exerts important protective effects against Ang II–induced AAA formation in apoE-deficient mice. Vitamin E led to a 44% decrease ($P < 0.05$) in the clinically important combined end point of fatal+nonfatal aortic rupture. Treatment with vitamin E also significantly decreased both the diameter and weight of AAAs in these mice. The reduction in aortic weight resulting from vitamin E treatment resulted, at least in part, from a diminution in the extent of macrophage infiltration and aortic rupture/thrombus formation. Although atherosclerotic lesions can affect the absolute aortic weight, there were no differences in the extent of atherosclerosis observed between the control and vitamin E groups. It should be emphasized that only animals surviving to the end of the 4-week infusion of Ang II were included in the analysis of AAA size. Furthermore, as rupture is an event linked to the size of the aneurysm, it is likely that the moderate reduction in AAA size produced by vitamin E therapy underestimates the true magnitude of its protective effect.

The murine Ang II–infusion model of AAA formation has attracted considerable interest for its potential relevance to human AAAs.^{9,10,23–25} For example, the development of AAAs in this model is associated with hyperlipidemia (ie, reported to occur in apoE-deficient or low-density lipoprotein receptor–deficient mice) and male sex.⁹ Also, histological features include leukocyte infiltration, medial degeneration, and thrombus formation, all of which are observed in human AAAs.⁹ On the other hand, AAAs commonly form in the suprarenal aorta in the murine Ang II–infusion model, in contrast to the infrarenal aorta in humans. In addition, AAAs in humans are characterized by luminal dilation and wall

thinning. Although luminal dilation has been demonstrated in the murine Ang II–infusion model by aortic ultrasonography in vivo and by pressure fixation techniques in vitro, thickening, rather than thinning, of the aortic wall is typically observed.²⁶ The wall thickening observed in the murine Ang II–infusion model is caused, in part, by hemorrhage into the aorta with associated thrombus formation, suggesting that the model may more closely resemble aortic dissection than common aneurysm formation in humans.

Several lines of evidence point to an increase in oxidative stress associated with AAA formation and/or progression. Using cDNA microarray analysis, Yajima et al detected upregulation of the expression of genes involved in oxidative stress in AAAs induced by elastase infusion in rats.²⁷ Nakahashi et al reported that parenteral supplementation with vitamin E in the rat elastase model reduced aortic enlargement and reactive oxygen species (ROS) production.²⁸ This latter study was conducted on a very small number of animals (just 3 rats were treated with vitamin E) and the efficacy of vitamin E to ameliorate clinical end points (ie, aneurysm rupture or mortality) was not examined. Human AAA tissues have also been reported to display evidence of increased oxidative stress.^{8,29} Moreover, plasma levels of vitamin E were markedly reduced in patients with AAAs but not in patients with coronary artery disease in the absence of AAAs.³⁰ Our group recently reported increased expression and activity of NADPH oxidase, an ROS generating enzyme, in human AAA as compared with adjacent nonaneurysmal aortic segments obtained from the same patients.⁸ Notably, Ang II has been shown to induce aortic oxidative stress by activating NADPH oxidase.^{31–34} In total, these studies suggest that ROS generated through NADPH oxidase may play an important role in formation of AAAs in animal models and in humans.

Here, we demonstrated that Ang II infusion markedly increased aortic isoprostane formation, which was significantly lowered by treatment with dietary vitamin E, confirming that vitamin E effectively reduced aortic oxidative stress in this animal model. Furthermore, this decrease in aortic oxidative stress was associated with amelioration of AAA

and its consequences. Notably, several clinical studies of antioxidants in humans have established a correlation between therapeutic efficacy and the capacity to ameliorate markers of oxidative stress.³⁵ However, we cannot exclude the possibility that the beneficial effects of vitamin E were attributable to mechanism(s) independent of its antioxidant properties. For example, vitamin E was shown to inhibit protein kinase C,³⁶ leading to impaired smooth muscle cell proliferation and diminished NADPH oxidase activity (which may indirectly reduce oxidative stress).

The data in this study provide some insight into the mechanisms by which oxidative stress might contribute to AAA formation in the Ang II-infusion model. First, Ang II is a potent inducer of superoxide, which contributes to the pressor response in mice.^{31–34} Hypertension is also an important factor in the genesis of AAAs in humans. However, treatment with vitamin E, which is not an efficient scavenger of superoxide, did not ameliorate Ang II-induced hypertension. This observation indicates that the mechanical forces produced by superoxide-induced hypertension are not solely responsible for induction of AAAs. Likewise, vitamin E did not affect lipid levels or attenuate atherosclerotic lesion formation. Together, these results suggest that oxidative stress most likely acts locally within the aortic wall to contribute to AAA formation in this model.

In vascular cells, Ang II is a potent inducer of chemotactic cytokines and adhesion molecules, which recruit inflammatory cells to vascular lesions. Histological studies have demonstrated infiltration of macrophages and other inflammatory cells into the aorta occurring in the very first days of Ang II infusion in hyperlipidemic mice, preceding the development of AAAs.¹⁸ We demonstrated that vitamin E significantly reduced macrophage infiltration into the abdominal aorta of Ang II-infused animals, which likely contributed to its protective effects with regard to AAA size and the extent of aortic rupture. Moreover, we demonstrated that vitamin E treatment markedly attenuated Ang II-induced upregulation of aortic OPN, a chemotactic cytokine that was recently implicated in Ang II-induced AAA formation in this model.²¹ In one previous study, ROS were reported to stimulate Ang II-induced OPN expression in cultured endothelial cells.²² Our study extends these prior findings and suggests that redox regulation of OPN expression may be an important mechanism linking oxidative stress to vascular disease *in vivo*. It is important to point out that several other cytokines and adhesion molecules have been reported to be redox-regulated^{37–39} and could potentially have been affected by treatment with vitamin E. However, unlike OPN, their role in AAA formation in this model has not been established.

Both resident smooth muscle cells and infiltrating inflammatory cells produce matrix metalloproteinases, in particular MMP-2 and MMP-9, which have been implicated in formation of AAAs,¹⁹ and their activities may be stimulated by ROS.²⁰ We, therefore, investigated whether vitamin E treatment inhibited the activity of MMP-2 and/or MMP-9 in aortic tissues. As expected, Ang II infusion markedly increased MMP-2 and MMP-9 activity in whole aorta homogenates. This increase in MMP activity was not, however, inhibited by treatment with vitamin E. It is important to point out that the

zymography was performed on equivalent amounts of aortic homogenates (determined by protein assay) from each group. Because the aortae from Ang II-treated mice were larger and contained more macrophages than those from mice treated with Ang II+vitamin E, it is likely that the absolute amount of MMP per aorta was, in fact, reduced by treatment with vitamin E. It is also possible that MMPs other than MMP-2 and -9 could be involved in Ang II-induced AAAs in this model. However, we did not see additional unidentified bands on the zymographs. Finally, the presence and/or activity of MMP inhibitors may differ between experimental groups. Additional studies are needed to address these possibilities.

Although vitamin E led to a significant decrease in AAAs, it did not attenuate atherosclerosis in the aortic root of Ang II-treated apoE-deficient mice. This is in contrast to previous studies reporting attenuation of atherosclerosis in hyperlipidemic mice treated with the same dose of vitamin E used in the present study.^{15,16} There are several potential explanations for this apparent discrepancy. The previous studies differed from the current study in dietary fat content, age, and genetic backgrounds of the mice, and the duration of vitamin E treatment. In addition, we quantified atherosclerosis only at the aortic root, and our findings are actually in agreement with some studies showing a lack of effect of vitamin E on atherosclerosis at this level.^{40,41} Most importantly, these prior studies were not performed on mice infused with Ang II, which is known to markedly increase the production of ROS.

In summary, we report that vitamin E protects against AAA formation in the murine Ang II-infusion model. These findings are consistent with the concept that oxidative stress may play a causal role in the pathogenesis of Ang II-driven AAAs in mice. Furthermore, these results suggest that additional basic and clinical research using vitamin E and other antioxidants is warranted to define the role of oxidative stress in the pathogenesis of AAAs.

Acknowledgments

This work was supported by NIH grants HL-62984 and HL-070860 (to N.L.W.); HL-62846 and HL-70239 (to A.D.); and Veterans Administration Merit Awards (to K.C.D. and N.L.W.). We are grateful to Deborah Howatt for analysis of atherosclerotic lesion size, to Dr Bridget Zimmerman for assistance with statistical analysis, and to Dr Sean Didion for assistance with SBP measurements.

References

- Lederle FA, Johnson GR, Wilson SE, Ballard DJ, Jordan WD Jr, Blebea J, Littooy FN, Freischlag JA, Bandyk D, Rapp JH, Salam AA; Veterans Affairs Cooperative Study #417 Investigators. Rupture rate of large abdominal aortic aneurysms in patients refusing or unfit for elective repair. *J Am Med Assoc.* 2002;287:2968–2972.
- Brewster DC, Cronenwett JL, Hallett JW Jr, Johnston KW, Krupski WC, Matsumura JS; Joint Council of the American Association for Vascular Surgery and Society for Vascular Surgery. Guidelines for the treatment of abdominal aortic aneurysms. Report of a subcommittee of the Joint Council of the American Association for Vascular Surgery and Society for Vascular Surgery. *J Vasc Surg.* 2003;37:1106–1117.
- Brophy CM, Reilly JM, Smith GJ, Tilson MD. The role of inflammation in nonspecific abdominal aortic aneurysm disease. *Ann Vasc Surg.* 1991; 5:229–233.
- Freestone T, Turner RJ, Coady A, Higman DJ, Greenhalgh RM, Powell JT. Inflammation and matrix metalloproteinases in the enlarging abdominal aortic aneurysm. *Arterioscler Thromb Vasc Biol.* 1995;15: 1145–1151.

5. Shah PK. Inflammation, metalloproteinases, and increased proteolysis: an emerging pathophysiological paradigm in aortic aneurysm. *Circulation*. 1997;96:2115–2117.
6. Newman KM, Jean-Claude J, Li H, Ramey WG, Tilson MD. Cytokines that activate proteolysis are increased in abdominal aortic aneurysms. *Circulation*. 1994;90(pt 2):II-224–II-227.
7. Koch AE, Haines GK, Rizzo RJ, Radosovich JA, Pope RM, Robinson PG, Pearce WH. Human abdominal aortic aneurysms. Immunophenotypic analysis suggesting an immune-mediated response. *Am J Pathol*. 1990;137:1199–1213.
8. Miller FJ Jr, Sharp WJ, Fang X, Oberley LW, Oberley TD, Weintraub NL. Oxidative stress in human abdominal aortic aneurysms: a potential mediator of aneurysmal remodeling. *Arterioscler Thromb Vasc Biol*. 2002;22:560–565.
9. Manning MW, Cassi LA, Huang J, Szilvassy SJ, Daugherty A. Abdominal aortic aneurysms: fresh insights from a novel animal model of the disease. *Vasc Med*. 2002;7:45–54.
10. Daugherty A, Manning MW, Cassi LA. Angiotensin II promotes atherosclerotic lesions and aneurysms in apolipoprotein E-deficient mice. *J Clin Invest*. 2000;105:1605–1612.
11. Hansen LG, Warwick WJ. An improved assay method for serum vitamins A and E using fluorometry. *Am J Clin Pathol*. 1978;70:922–923.
12. Daugherty A, Whitman SC. Quantification of atherosclerosis in mice. *Methods Mol Biol*. 2003;209:293–309.
13. Zhang HJ, Zhao W, Venkataraman S, Robbins ME, Buettner GR, Kregel KC, Oberley LW. Activation of matrix metalloproteinase-2 by overexpression of manganese superoxide dismutase in human breast cancer MCF-7 cells involves reactive oxygen species. *J Biol Chem*. 2002;277:20919–20926.
14. Li WG, Gavrila D, Liu X, Wang L, Gunnlaugsson S, Stoll LL, McCormick ML, Sigmund CD, Tang C, Weintraub NL. Ghrelin inhibits proinflammatory responses and nuclear factor-kappaB activation in human endothelial cells. *Circulation*. 2004;109:2221–2226.
15. Pratico D, Tangirala RK, Rader DJ, Rokach J, FitzGerald GA. Vitamin E suppresses isoprostane generation in vivo and reduces atherosclerosis in ApoE-deficient mice. *Nat Med*. 1998;4:1189–1192.
16. Cyrus T, Yao Y, Rokach J, Tang LX, Pratico D. Vitamin E reduces progression of atherosclerosis in low-density lipoprotein receptor-deficient mice with established vascular lesions. *Circulation*. 2003;107:521–523.
17. Pratico D, Reilly M, Lawson JA, FitzGerald GA. Novel indices of oxidant stress in cardiovascular disease: specific analysis of F2-isoprostanes. *Agents Actions Suppl*. 1997;48:25–41.
18. Saraff K, Babamusta F, Cassi LA, Daugherty A. Aortic dissection precedes formation of aneurysms and atherosclerosis in angiotensin II-infused, apolipoprotein E-deficient mice. *Arterioscler Thromb Vasc Biol*. 2003;23:1621–1626.
19. Longo GM, Xiong W, Greiner TC, Zhao Y, Fiotti N, Baxter BT. Matrix metalloproteinases 2 and 9 work in concert to produce aortic aneurysms. *J Clin Invest*. 2002;110:625–632.
20. Rajagopalan S, Meng XP, Ramasamy S, Harrison DG, Galis ZS. Reactive oxygen species produced by macrophage-derived foam cells regulate the activity of vascular matrix metalloproteinases in vitro. Implications for atherosclerotic plaque stability. *J Clin Invest*. 1996;98:2572–2579.
21. Brummer D, Collins AR, Noh G, Wang W, Territo M, Arias-Magallona S, Fishbein MC, Blaschke F, Kintscher U, Graf K, Law RE, Hsueh WA. Angiotensin II-accelerated atherosclerosis and aneurysm formation is attenuated in osteopontin-deficient mice. *J Clin Invest*. 2003;112:1318–1331.
22. Xie Z, Pimental DR, Lohan S, Vasertriger A, Pligavko C, Colucci WS, Singh K. Regulation of angiotensin II-stimulated osteopontin expression in cardiac microvascular endothelial cells: role of p42/44 mitogen-activated protein kinase and reactive oxygen species. *J Cell Physiol*. 2001;188:132–138.
23. Daugherty A, Manning MW, Cassi LA. Antagonism of AT2 receptors augments angiotensin II-induced abdominal aortic aneurysms and atherosclerosis. *Br J Pharmacol*. 2001;134:865–870.
24. Martin-McNulty B, Tham DM, da Cunha V, Ho JJ, Wilson DW, Rutledge JC, Deng GG, Vergona R, Sullivan ME, Wang YX. 17 β -estradiol attenuates development of angiotensin II-induced aortic abdominal aneurysm in apolipoprotein e-deficient mice. *Arterioscler Thromb Vasc Biol*. 2003;23:1627–1632.
25. Deng GG, Martin-McNulty B, Sukovich DA, Freay A, Halks-Miller M, Thinnes T, Loskutoff DJ, Carmeliet P, Dole WP, Wang YX. Urokinase-type plasminogen activator plays a critical role in angiotensin II-induced abdominal aortic aneurysm. *Circ Res*. 2003;92:510–517.
26. Wang YX, Martin-McNulty B, Freay AD, Sukovich DA, Halks-Miller M, Li WW, Vergona R, Sullivan ME, Morser J, Dole WP, Deng GG. Angiotensin II increases urokinase-type plasminogen activator expression and induces aneurysm in the abdominal aorta of apolipoprotein E-deficient mice. *Am J Pathol*. 2001;159:1455–1464.
27. Yajima N, Masuda M, Miyazaki M, Nakajima N, Chien S, Shyy JY. Oxidative stress is involved in the development of experimental abdominal aortic aneurysm: a study of the transcription profile with complementary DNA microarray. *J Vasc Surg*. 2002;36:379–385.
28. Nakahashi TK, Hoshina K, Tsao PS, Sho E, Sho M, Karwowski JK, Yeh C, Yang RB, Topper JN, Dalman RL. Flow loading induces macrophage antioxidative gene expression in experimental aneurysms. *Arterioscler Thromb Vasc Biol*. 2002;22:2017–2022.
29. Dubick MA, Keen CL, DiSilvestro RA, Eskelson CD, Ireton J, Hunter GC. Antioxidant enzyme activity in human abdominal aortic aneurysmal and occlusive disease. *Proc Soc Exp Biol Med*. 1999;220:39–45.
30. Sakalihan N, Pincemail J, Defraigne JO, Nussgens B, Lapiere C, Limet R. Decrease of plasma vitamin E (alpha-tocopherol) levels in patients with abdominal aortic aneurysm. *Ann NY Acad Sci*. 1996;800:278–282.
31. Zafari AM, Ushio-Fukai M, Akers M, Yin Q, Shah A, Harrison DG, Taylor WR, Griendling KK. Role of NADH/NADPH oxidase-derived H₂O₂ in angiotensin II-induced vascular hypertrophy. *Hypertension*. 1998;32:488–495.
32. Wang HD, Xu S, Johns DG, Du Y, Quinn MT, Cayatte AJ, Cohen RA. Role of NADPH oxidase in the vascular hypertrophic and oxidative stress response to angiotensin II in mice. *Circ Res*. 2001;88:947–953.
33. Wang HD, Johns DG, Xu S, Cohen RA. Role of superoxide anion in regulating pressor and vascular hypertrophic response to angiotensin II. *Am J Physiol Heart Circ Physiol*. 2002;282:H1697–H1702.
34. Mollnau H, Wendt M, Szocs K, Lassegue B, Schulz E, Oelze M, Li H, Bodenschatz M, August M, Kleschyov AL, Tsilimingas N, Walter U, Forstermann U, Meinertz T, Griendling K, Munzel T. Effects of angiotensin II infusion on the expression and function of NAD(P)H oxidase and components of nitric oxide/cGMP signaling. *Circ Res*. 2002;90:e58–e65.
35. Jialal I, Devaraj S. Antioxidants and atherosclerosis: don't throw out the baby with the bath water. *Circulation*. 2003;107:926–928.
36. Azzi A, Ricciarelli R, Zingg JM. Non-antioxidant molecular functions of alpha-tocopherol (vitamin E). *FEBS Lett*. 2002;519:8–10.
37. Rosenblat M, Aviram M. Oxysterol-induced activation of macrophage NADPH-oxidase enhances cell-mediated oxidation of LDL in the atherosclerotic apolipoprotein E deficient mouse: inhibitory role for vitamin E. *Atherosclerosis*. 2002;160:69–80.
38. Jialal I, Devaraj S, Kaul N. The effect of alpha-tocopherol on monocyte proatherogenic activity. *J Nutr*. 2001;131:389S–394S.
39. Islam KN, Devaraj S, Jialal I. Alpha-tocopherol enrichment of monocytes decreases agonist-induced adhesion to human endothelial cells. *Circulation*. 1998;98:2255–2261.
40. Paul A, Calleja L, Joven J, Vilella E, Ferre N, Camps J, Girona J, Osada J. Supplementation with vitamin E and/or zinc does not attenuate atherosclerosis in apolipoprotein E-deficient mice fed a high-fat, high-cholesterol diet. *Int J Vitam Nutr Res*. 2001;71:45–52.
41. Shaish A, George J, Gilburd B, Keren P, Levkovitz H, Harats D. Dietary beta-carotene and alpha-tocopherol combination does not inhibit atherogenesis in an ApoE-deficient mouse model. *Arterioscler Thromb Vasc Biol*. 1999;19:1470–1475.